

Technical Innovation

Sonographically Guided Needle Localization After Stereotactic Breast Biopsy

Dana H. Whaley¹, Darcy L. Adamczyk, Eric A. Jensen

Imaging-guided vacuum-assisted breast biopsy has become a common radiologic procedure [1]. This procedure can now be performed with either stereotactic or sonographic guidance. When malignant or suspicious pathologic findings are detected, surgical resection is usually indicated. Because all or most of the lesion may be removed during the initial biopsy, a marking device is frequently needed to assist in subsequent needle localization procedures. Previously, this has been accomplished with a metal clip placed through the vacuum device at the time of biopsy [2, 3]. Any subsequent needle localization procedure then uses mammographic imaging techniques. We prefer to use sonographic imaging to guide needle localizations whenever possible because sonographic guidance causes less patient discomfort and is less time-consuming. This option is now possible with the use of a new marking device that can be imaged on either sonography or mammography.

Materials and Methods

The new marking device (Gel Mark Ultra; SenoRx, Aliso Viejo, CA) is composed of 11 small biodegradable cylinders, with the middle one containing a stainless steel wire. The wire has a distinctive shape: a circle that has a short arm and a

long arm. The marker is composed of a synthetic compound (copolymer of polylactic acid and polyglycolic acid) that is similar to Vicryl suture (Ethicon Endo-Surgery, Cincinnati, OH). Embedded within the wire cylinders are carbon dioxide bubbles that make the marker highly echogenic and therefore detectable on sonography (technical report #2; SenoRx). This Vicryl-like compound is easy to see on sonography and is used in place of collagen, which was used in an earlier version of this product. This compound has been shown to remain visible for at least 4 weeks (Lechner M et al., presented at the 19th Annual Miami Breast Conference, Miami Beach, FL, February 2002). Over several months, this material degrades so that it is no longer visible on sonography; however, the metal marker is permanent, as with other wire marking devices [4, 5].

We recently used this device in a 50-year-old woman with two separate suspicious clusters of microcalcifications (Breast Imaging Reporting and Data System [BI-RADS] category 4 lesions [6]) in the right breast. These suspicious clusters were biopsied using an 11-gauge vacuum-assisted biopsy device (Mammotome; Ethicon Endo-Surgery) using standard techniques with the patient on a prone stereotactic table (Lorad, Danbury, CT). The patient experienced no complications.

At the completion of each biopsy, the needle was withdrawn approximately 5 mm, and the new marking device applicator was placed into the biopsy needle as far as possible. The markers were deployed with a gentle injection motion of the applicator han-

dle. The presence of the clip was verified on digital imaging, and the needle was removed.

The second cluster of microcalcifications was then biopsied using the same techniques (Fig. 1A). After completing the procedure, we obtained craniocaudal, mediolateral oblique, and mediolateral mammograms to evaluate the position of the markers. By comparing the mammograms obtained before biopsy with those obtained after biopsy, we verified that both markers were in the proper location at the biopsy sites. Both biopsy areas were evaluated with standard- and real-time compound-angle computed sonographic imaging (HDI 5000 with SonoCT; Advanced Technology Laboratories, Bothell, WA) (Figs. 1B and 1C). Sonography showed the cylinders to be highly echogenic and to have prominent posterior shadowing, which made the markers easy to identify at both locations.

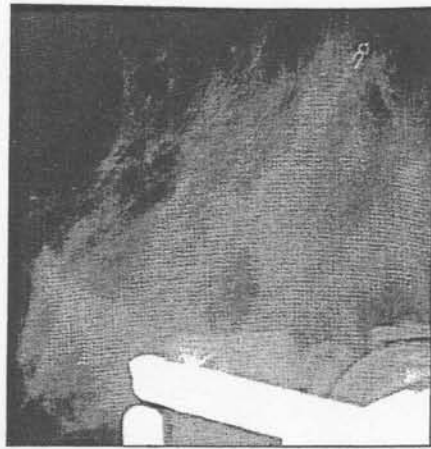
Results

Pathologic evaluation showed both biopsy sites to be intermediate-grade ductal carcinoma in situ, so surgical treatment was arranged. Needle localization (modified Kopan's Spring Hook; Cook, Bloomington, IN) of both regions was requested and performed 14 days after biopsy using only sonographic guidance. During localization, both areas were again easily visualized using both standard- and real-time compound-angle computed sonographic techniques (Figs. 1D and 1E). Mammograms were obtained

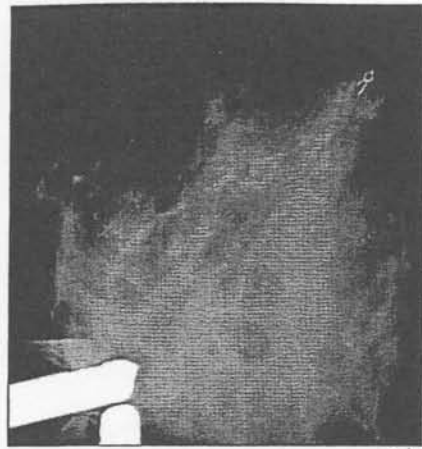
Received May 16, 2002; accepted after revision July 23, 2002.

¹All authors: Department of Radiology, Mayo Clinic, 200 First St. S.W., Rochester, MN 55905. Address correspondence to D. H. Whaley.

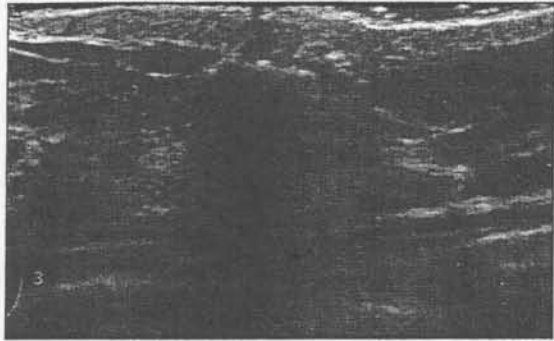
AJR 2003;180:352-354 0361-803X/03/1802-352 © American Roentgen Ray Society



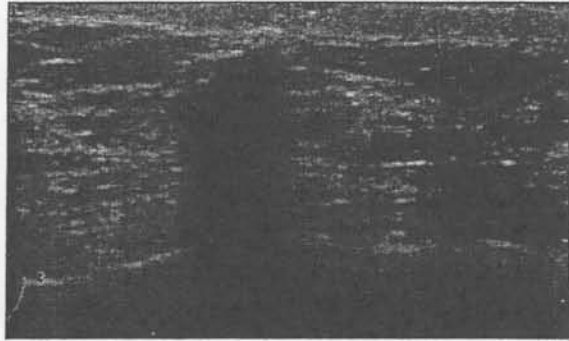
A



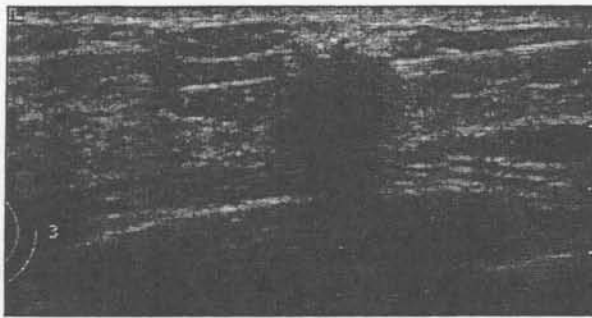
B



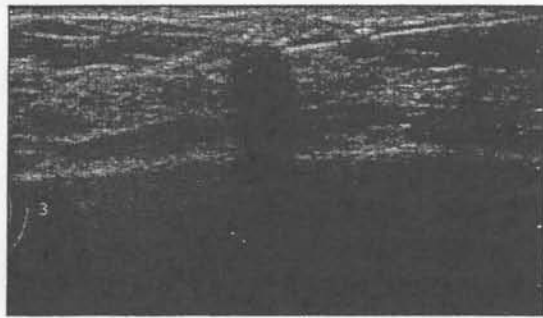
C




D



E



F



G

Fig. 1.—50-year-old woman with suspicious clusters of microcalcifications in right breast. **A and B,** Digital mammographic images obtained during stereotactic biopsy show marker clip in first area of calcifications after biopsy (**A**) and second area of calcifications before biopsy gun was fired (**B**). **C and D,** Longitudinal real-time compound sonographic image (**C**) shows most inferior biopsy site, and transverse conventional sonographic image (**D**) shows second biopsy site. Both images were obtained shortly after marker placement. **E,** Transverse real-time compound sonographic image shows first site. **F,** Transverse conventional sonographic image of second site shows needle placement for surgery 14 days after stereotactic biopsy. **G,** Craniocaudal mammogram shows both biopsy clips and needle localization wires before surgical removal.

after localization to assist with surgery (Fig. 1F). Complete surgical removal was subsequently accomplished without difficulty.

Discussion

Improvements in percutaneous biopsy techniques have made it increasingly necessary to accurately mark the site of a breast lesion at biopsy. The option to perform needle localization procedures with sonography and mammography equipment adds needed flexibility and increases patient flow in a radiology department. The combination of high echogenicity and prominent shadowing offered by this device allowed it to be used for needle localization under sonographic guidance 14 days after stereotactic biopsy. Using both standard- and real-time compound-angle computed sonographic imaging, we could easily and definitively iden-

tify the cylinder-shaped markers. The distinctive appearance of the metallic marker in this device can also be used to distinguish it from other currently available markers and allow multiple lesions to be accurately marked by different devices.

Since this initial case, we have placed more than 40 of these devices in patients who subsequently required surgery. In six patients, the marker was used to complete the needle localization procedure using sonographic guidance. Three of these markers were placed at stereotactic biopsy, and three were placed with a hand-held vacuum device (Mammotome; Ethicon Endo-Surgery) using sonographic guidance. We look forward to future comprehensive evaluation and comparison of the strengths and weaknesses of this and other new biopsy markers.

References

1. Burbank F, Parker S, Fogarty T. Stereotactic breast biopsy: improved tissue harvesting with the mammotome. *Am Surg* 1996;62:128-150
2. Burbank F, Forcier N. Tissue marking clip for stereotactic breast biopsy: initial placement accuracy, long-term stability, and usefulness as a guide for wire localization. *Radiology* 1997;205:407-415
3. Liberman L, Dershaw DD, Morris EA, Abramson AF, Thornton CM, Rosen PP. Clip placement after stereotactic vacuum-assisted breast biopsy. *Radiology* 1997;205:417-422
4. Penco M, Marcioni S, Ferruti P, D'Antone S, Deghenghi R. Degradation behaviour of block copolymers containing poly (lactic-glycolic acid) and poly (ethylene glycol) segments. *Biomaterials* 1996;17:1583-1590
5. Vert M, Li S, Garreau H. New insights on the degradation of bioresorbable polymeric devices based on lactic and glycolic acids. *Clin Mater* 1992;10:3-8
6. American College of Radiology. *Breast imaging reporting and data system (BI-RADS)*, 3rd ed. Reston, VA: American College of Radiology, 1998

The 2003 ARRS Annual Meeting will include an intensive neuroradiology review.