

Surgical Benefits Conveyed by Biopsy Site Marking System Using Ultrasound Localization

Nurko, J.¹; Mancino, A.T.¹; Whitacre, E.B.²; and Edwards, M.¹

¹University of Arkansas for Medical Sciences

²The Breast Center of Southern Arizona

Background

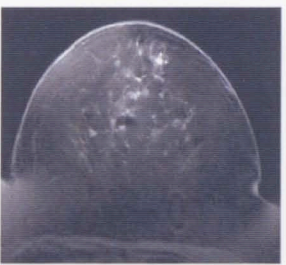
With vacuum assisted biopsy technology all, or most, of a breast lesion may be removed during the initial biopsy; in such cases a metallic marker is often inserted at the site of the biopsy for future localization but not visible on ultrasound. The aim of this study was to evaluate the efficacy and impact of the Gel Mark Ultra™ biopsy site marking system (Senorix, Aliso Viejo, CA) on the practice of needle localization breast biopsy.

Methods

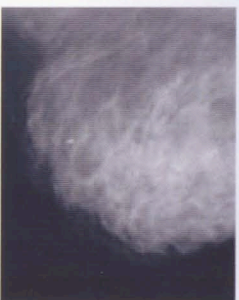
We retrospectively analyzed the experience of 45 broad based general surgeons across the United States in a variety of practice settings using the Gel Mark Ultra™ biopsy site marking system. Imaging-guided biopsy technique, localization quality, surgeon confidence and margin status were assessed and compared against the broad data reported in the literature.

Results

A total of 432 records of patients that underwent imaging guided breast biopsy with placement of Gel Mark Ultra™ biopsy site marking system were reviewed. Of these, 63 (15%) patients required definitive surgical intervention; of those, 44 were localized with ultrasound. Margin status was available in all but 3 cases. Clear margins were achieved in 37(90%) of the 41 cases. These results are statistically superior ($p < .01$) to the rate of positive margins calculated from the cumulative experience reported in the literature, (ranging between 12 to 55%).²⁻⁶



Top: Mammographic visualization of Gel Mark Ultra™ clip marking the previous biopsy site.



Bottom: MRI-compatible clip for identification of the biopsy site.

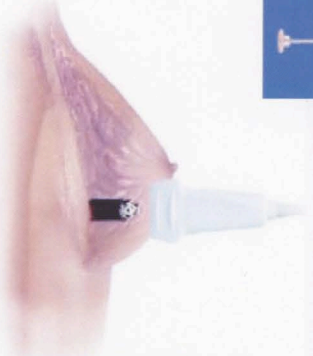

Left: Picture of the syringe-like applicator of the Gel Mark Ultra™ clip.

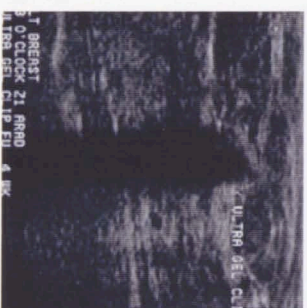

Middle: Picture of the pellet containing the metallic clip.

Right: Mammographic image with visualization of the clip after absorbable pellets have dissolved within the breast tissue.



Picture demonstrating proper placement of ultrasound probe and intraoperative localization of the biopsy site.



Ultrasound picture demonstrating the posterior shadowing produced by the reabsorbable pellets.

Histopathological Results that Require Surgical Intervention

INDICATION FOR OPERATION	#, (%) CASES
ATYPICAL HYPERPLASIA	10 (16)
DCIS	19 (30)
INVASIVE CA	28 (44)
LCIS	1 (2)
OTHER*	5 (8)
TOTAL	63

* BRISQ5, Simplex papillary sclerosing/ fusion, infiltrating ductal carcinoma, Tubular carcinoma and Fibroadenoma

Conclusions

Gel Mark Ultra™ biopsy site marking system is a new biopsy site localization device that provides a safe and effective alternative to traditional localization methods. More importantly it provides a significant reduction in the frequency of positive margins, as well as enhancing surgical efficiency and patient comfort.

References

- Burbank, E, Fortier, N. Tissue marking clip for stereotactic breast biopsy: initial placement accuracy, long-term stability, and usefulness as a guide for wire localization. *Radiology*. 1997; 205(2):407-15.
- Mokbel K, Choy C, et al. Predictors of positive margins after local excision of ductal carcinoma in situ. *Am J Surg*. 2001 Feb; 181(2):91-5.
- Anscher MS, Jones P, et al. Local failure and margin status in early-stage breast carcinoma treated with conservation surgery and radiation therapy. *Ann Surg*. 1993 Jul; 218(1):22-8.
- Tartert PJ, Kaplan J, et al. Lumpectomy margins, reexcision, and local recurrence of breast cancer. *Am J Surg*. 2000 Feb; 179(2):81-5.
- Lee CH, Carter D, et al. Detecting residual tumor after excisional biopsy of impalpable breast carcinoma: efficacy of comparing preoperative mammograms with radiographs of the biopsy specimen. *Am J Surg*. 1995 Jan; 164(1):181-6.
- Mulliken PS, Caudrudo DG, et al. Secondary operations are frequently required to complete the surgical phase of therapy in the era of breast conservation and sentinel lymph node biopsy. *Am J Surg*. 2004 May; 187(5):643-6.